Endo-Ease Discovery SB

Training Manual

spirus™ medical

History

Introduction

Preparation and Installation

Insertion

Rotational Advancement

Withdrawal

Summary Points

There are several indications necessitating the need for small bowel endoscopy, but Obscure Gastrointestinal Bleeding (OGIB) remains the most common. Patients with OGIB are difficult to diagnose and managing their treatment can be challenging. Often these patients require repeated blood transfusions and recurring hospital visits. The path to diagnosis often involves multiple diagnostic procedures that burden our healthcare resources and raise questions about patient quality of life.

The introduction of Capsule Endoscopy (CE) in 2001, followed by Double Balloon Enteroscopy (DBE) a few years later, radically changed the way the small bowel is diagnosed and treated. CE has proven to be an effective tool to identify small bowel abnormalities and their approximate location. Patients with lesions estimated to be beyond the reach of push enteroscopy are often referred for a DBE. It has been reported that a complete small bowel enteroscopy with DBE is possible, however, widespread experience has shown this is not the norm. Moreover, DBE remains a technically challenging procedure, often requiring extensive time and resources to complete.

Close-up of the Discovery SB's smooth, hollow spirals.

The Endo-Ease Discovery® SB is a revolutionary over-tube system that enables physicians to perform enteroscopy procedures more efficiently. A smooth, compliant spiral located at the distal end of the tube rapidly gathers and pleats the small bowel. Antegrade enteroscopic introduction with the Endo-Ease Discovery SB helps to advance compatible enteroscopes beyond the Ligament of Treitz, the fixed portion of small bowel at the end of the duodenum. Rotating the Discovery SB beyond the LOT allows the spiral to pleat the small bowel in a rapid and controlled manner. The Endo-Ease Discovery SB permits the enteroscope to be independently maneuvered while the overtube remains in place, which is especially useful during piecemeal polypectomy. During this demanding procedure the Discovery SB holds the gathered small bowel in place while the enteroscope is removed with a section of the large polyp through the overtube. The scope is then quickly reinserted to its previous location to excise the remaining portions of a large lesion–a technique not possible with DBE.

Discovery SB shown with scope.

The Spirus Medical Endo-Ease Discovery SB (DSB) is an instrument designed to facilitate antegrade small bowel enteroscopy. The DSB is 118cm long and 48 French in diameter with a raised helical element at its distal end that is 21 cm long. Two models of the DSB are available and differ only in the height of the spiral. The standard profile spiral is 5.5mm and is expected to be the choice for the majority of DSB cases. The low profile spiral (4.5mm) is slightly smaller to accommodate varying patient anatomies.

Deep advancement into the small bowel can be achieved via clockwise rotation of the DSB around the enteroscope which pleats the small bowel. This is defined as spiral enteroscopy (SE). The DSB's Gentle-Lock proximal coupler permits fixing the Discovery SB to the enteroscope for spiral advancement or unlocking to permit pushing of the enteroscope through the DSB. The DSB provides rotational advancement, stability and control capabilities. The enteroscope can be manipulated as in conventional endoscopy. This includes forward and backward movement, tip deflection, rotation of the scope, air/suction, insufflation and full use of the accessory channel. The DSB is designed to be used with 200 cm long enteroscopes with an outer diameter range of 9.1mm-9.5mm. The DSB allows all standard therapies to be employed.

Sedation Recommendations

- Use of propofol is strongly recommended at least until device mastery is obtained.
- Make sure propofol is maintained through the end of the case as the spiral is coming out of the esophagus. This helps prevent any trauma from occurring due to the patient tensing up or from their movements.
- Use lidocaine spray 5 min before every DSB procedure. This will aid in ease of passage of the DSB and relaxation of the patient.
- If general anesthesia is administered deflate the endotracheal tube balloon when passing the Discovery SB spiral through the esophagus during both initial insertion and withdrawal. This will minimize any "sandwiching" of tissue between the balloon and Discovery SB.

1. To begin, the patient is placed in a left lateral decubitus position and the neck slightly extended to optimize a straight initial pathway. Insert the bite block and fix in place by fastening the elastic band around the patient's head.

2. Before installing the DSB onto the enteroscope, squeeze a minimum of one ounce of recommended lubricant into the over-tube via the DSB's proximal coupler. Cover both ends of the tube with your thumbs. Vigorously work the mixture back and forth through the entire length. Evenly lubricate the outside of the enteroscope and insert it into the proximal (non-spiral) end of the DSB.

3. Rotate the DSB during the installation of the enteroscope. Hold the distal end of the DSB to the proximal coupling to allow excess lube to be recycled back into the DSB. Be sure to push and pull the scope through the DSB multiple times to ensure that there is no resistance. If resistance is encountered it may be an indicator of insufficient lubrication. The enteroscope should move freely and easily before it is used. The enteroscope can be relubricated with the remaining lubricant via the flush port on the DSB.

Lubricant syringe.

4. The DSB should be positioned over the scope so that the 140cm mark of the enteroscope is lined up with the proximal end of the DSB. Turn the Gentle-Lock coupler located at the proximal end of the DSB clockwise and lock the DSB onto the enteroscope so that the DSB and scope are joined together as a coupled device. Note the centimeter point on the endoscope just proximal to the Gentle-Lock coupler for future reference when disengaging and re-engaging the enteroscope from the DSB.

5. Generously lubricate the spiral with K-Y Jelly® before insertion and continue applying evenly along the entire length of the DSB as it is being inserted.

1. Place the patient in left lateral decubitus position with the neck slightly extended and the Spirus mouth guard inserted. Lock the Discovery SB onto the enteroscope at the 140 cm mark (viewed on the enteroscope just behind the DSB's coupler).

2. Verify that the endoscope and DSB spiral are lubricated with K-Y Jelly.

3. Introduce the endoscope until the DSB spiral element reaches the mouth.

4. Utilizing fingertip control, gently introduce the DSB into the esophagus with gentle, slow rotation and push.

▶ *If using general anesthesia, let down the endotracheal ballon as the spiral passes through the esophagus, then reinsufflate.*

5. Advance the DSB utilizing slow clockwise rotation and gentle push. Minimize air insufflation and attempt to advance along the lesser curvature of the stomach to minimize looping and optimize the chance for early introduction of the spirals into the jejunum. Prior to entering the duodenum remove as much air as possible.

Figure 1: Discovery SB is introduced with clockwise rotation and gentle push.

▶ *Never advance the locked DSB without visualization of the lumen or against excessive resistance. Abdominal counter-pressure is often helpful applied to the greater curvature of the stomach for loop reduction to facilitate initial spiral engagement.*

6. Advance the coupled Discovery SB and enteroscope with slow gentle rotation and push until the proximal small bowel is reached or rotation becomes difficult.

At this point consider attempting to begin spiral enteroscopy. Typically there is a loop in the stomach that prevents the optimum straight scope position. Rotation with gentle withdrawal of the Discovery SB may help advance the scope and begin engagement of spiral enteroscopy (we call this the Cantero Maneuver).

When the Discovery SB is in a straight position, usually at the 50-65cm mark at the patients mouth, and if spiral enteroscopy is not initiated, gentle push to advance is attempted with slow rotation.

Spiral enteroscopy is then attempted. This gentle rotation and push to advance of the coupled device is usually attempted 2-4 times. If spiral advancement is not successful, abdominal counter-pressure may be helpful in preventing looping and initiating spiral enteroscopy.

7. If this is not successful in initiating spiral enteroscopy, we recommend using the following "over the scope" technique to attempt to advance the spirals past the Ligament of Treitz (LOT) and begin spiral enteroscopy.

8. The "over the scope" technique is performed as follows: With the tip of the enteroscope in the proximal small bowel, unlock the enteroscope from the DSB and advance the enteroscope to the maximal depth of insertion, usually past the LOT to the proximal jejunum.

Apply hook and continuous suction to hold the enteroscope to the wall of the small bowel. At the same time, pull back the enteroscope and advance the DSB with gentle clockwise rotation and gentle push until the 130 to 140cm mark on the scope is reached by the DSB proximal coupler.

Figure 2: Loop formation in the stomach.

Figure 3: Clockwise rotation with gentle pullback reduces the loop and engages the spiral in the duodenum.

LOCK the DSB to the enteroscope. The tip of the enteroscope should now be in the proximal jejunum. Clockwise rotation may now initiate spiral enteroscopy. A loop may have formed in the stomach and gentle withdrawal of the scope may straighten the Discovery SB and advance the locked device to begin spiral enteroscopy.

Note: *You may attempt the Cantero Maneuver 2 to 3 times as explained in step 5 before repeating the "over the scope technique" explained above.*

9. Keys to early engagement include avoiding air insufflations, advancing the locked DSB/enteroscope only when the lumen is visualized and utilizing abdominal counterpressure to prevent looping in the stomach. When utilizing the Cantero Maneuver, the DSB may need to be pulled back as far as 55 cm, as measured on the DSB at the mouth, to achieve a straight scope position. With the DSB locked to the enteroscope attempt rotational advancement.

10. If unsuccessful repeat steps 4 through 8.

▶ *Remember, never advance the locked DSB without visualization of the lumen.*

KEY *tips*

For successful introduction of the DSB and enteroscope

Excessive resistance rotating the DSB early in the procedure is almost always from a loop formation in the stomach; slow, careful and deliberate advancement through the upper GI tract is required for success.

Rapid turning of the DSB will never initiate engagement. If rotational advancement is not successful it is because the spiral element needs to be advanced further into the small bowel.

If spiral advancement begins but stops early in the procedure it usually means that the spiral element needs to be advanced a little further into the small bowel. This may happen with a sharp angle at the LOT, where only part of the spiral is past the LOT.

1. Rotate the DSB at a moderate pace. Applying very light traction may assist effective advancement.

2. Minimize enteroscope air insufflations and remove as much air as possible during spiral advancement as this inhibits pleating of the small bowel.

3. Use water injection for better visualization of the small bowel.

4. When rotational advancement slows consider that the spiral may need to be advanced slightly further into the small bowel. Occasionally a loop has formed and Cantero maneuver is needed to reduce the loop and get paradoxical advancement.

5. When rotation of the DSB is no longer effective, unlock the DSB from the enteroscope and push the enteroscope through the DSB to advance. Additional lubrication of the endoscope utilizing the DSB's lubrication port is often needed to advance the enteroscope through the DSB due to the "squeegee" effect of the Gentle-lock coupler gasket.

6. Apply hook and continuous suction of the enteroscope and pull the enteroscope back while rotating the DSB clockwise at a moderate pace. Pull back the enteroscope until it reaches the ~140 cm mark or significant slippage occurs. Note: Unlike in the duodenum gentle push of the DSB is not needed while turning clockwise since the DSB is already at maximum depth.

Figure 4: Discovery SB pleating the small bowel.

7. Repeat steps 5 and 6 until no further advancement is achieved. Once advancement is no longer successful using the above technique, or if rotation becomes difficult, the maximal depth of insertion has been reached.

KEY *tips*

For successful advancement

- Minimize air insufflations; inject water for luminal visualization.
- Rotate at a moderate pace and do not over-steer the enteroscope because it will rub against the bowel wall and slow down advancement.
- When advancing the enteroscope through the DSB add lubrication to the entry point behind the proximal coupler. Move the enteroscope back and forth slightly (jiggle) a few times to lubricate the gasket.
- If torque fatigue or buckling of DSB occurs it means that too much turning of the DSB has occurred against resistance. Utilize counter-clockwise rotation to reduce the DSB's resistance to rotation by reducing loops.
- If the enteroscope begins to rotate when the DSB is rotated it means there is increased friction on the enteroscope causing the enteroscope to not move freely inside the DSB. This may be due to insufficient lubrication, a sharp angulation of the coupled device, DSB torque fatigue/buckling, or the thicker bending section of the enteroscope has been pulled back into the DSB. In these situations, inject lubrication, reduce loops and monitor for increased friction. If the enteroscope/DSB friction still occurs consider maximal insertion has been reached and begin removal of the DSB/enteroscope.

1. Unlock the DSB and slowly pull the enteroscope back through the DSB to the ~140 cm mark while examining the small bowel. For maximal visualization, side to side sweep of enteroscope tip can easily be accomplished using angulation and torque of the enteroscope within the DSB.

2. Lock the DSB to the enteroscope at the ~140 cm mark and remember that the tip of the enteroscope is now ~22 cm from the tip of the spiral element.

3. Begin counter-clockwise rotation. Proceed VERY slowly, usually one 360 degree turn followed by waiting 3-5 seconds. Remember that the scope tip is 22 cm from the end of the DSB and there is a delay before the released small bowel reaches the tip of the enteroscope.

▶ *The enteroscope may have 2-4 meters of pleated small bowel behind the spiral element. When using counter-clockwise rotation, gently push the DSB forward to resist allowing the coupled device to come out. It may help to visualize push-off of the small bowel with counter-clockwise rotation. Initially, try to maintain the DSB's insertion position (reference the CM mark at the mouth) when withdrawing until counter-clockwise rotation is no longer effective.*

Figure 5: Counter-clockwise rotation while holding depth position.

4. After counterclockwise withdrawal while maintaining the DSB position at the mouth is no longer effective for withdrawal, slowly allow the DSB to come back utilizing counter-clockwise rotation until the DSB ~55 cm mark is reached (at the mouth). At this point the proximal spiral will be in the stomach near the gastroesophageal junction.

5. Unlock the enteroscope from the DSB and gently pull it back through the DSB withdrawing the enteroscope through the proximal jejunum, LOT and duodenum. This maneuver allows careful visualization of the duodenum. Pull back the enteroscope until it reaches the ~130 cm mark and lock the DSB to the enteroscope.

6. Begin slow counter-clockwise rotation and withdrawal of the DSB through the esophagus.

▶ *If using general anesthesia, let down the endotracheal balloon as the spiral passes through the esophagus, then reinsufflate.*

KEY *tips*

For successful withdrawal

- NEVER PULL THE DSB BACK WITHOUT COUNTER-CLOCKWISE ROTATION!
- If the patient is intubated, let down the balloon on the endotrachial tube as the spiral passes the endotracheal balloon on both insertion and withdrawal.

1. Minimize air insufflation! Insufflation limits the ability of the device to pleat small bowel by 2 modalities: decreased engagement of the spiral component and difficulty in compressing the pleated small bowel.

2. Go slowly early in the procedure and allow the endoscopist to lead the way through key areas: stomach, pylorus, bulb to second part of duodenum, around the third part of the duodenum. This minimizes looping.

3. Always try to keep a short, straight scope. This is particularly important when the spiral advancement is first initiated.

4. Always assume looping of the Discovery SB is responsible any time turning is difficult. Relieve the pressure by attempting to remove the loop. Turning harder is almost never the answer, although turning with moderate difficulty may be necessary for spiral advancement when the Discovery SB is deep in the small bowel.

5. Looping in the stomach can be removed by a variety of techniques including:

- Clockwise rotation with pulling back the DSB Cantero maneuver)
- Abdominal pressure
- Straight pullback if the device has resistance with clockwise or counter-clockwise rotation
- Over-the-scope technique

6. Always be aware of the position of the spiral with respect to the distance from the mouth and the distance from the tip of the scope. The spiral segment is 22cm in length and is positioned at the distal end of the DSB. The proximal end of the spiral is positioned 70cm distal to the green handle rendering a total working length of 92cm. The overall length of the DSB (including the green handle and Gentle-lock coupler) is 118cm. For example, if the

enteroscope's 130 mark is observed just proximal to the DSB's Gentle-lock coupler then there is 12cm of enteroscope protruding from the tip of the DSB.

7. If there is only a small amount of advancement with spiraling, then consider that the spiral is not advanced far enough past the LOT. The spiral may need to be advanced further to get advancement. A technique such as unlocking the DSB and advancing the enteroscope maximally with subsequent "hook, suction, and spiraling" may be needed to get a little deeper intubation of the DSB to get good spiral enteroscopy engagement.

8. Apply more DSB lubricant at the scope shaft proximal to the locking device during the procedure to facilitate scope advancement through the DSB. K-Y Jelly lubricant on the DSB shaft should be liberally and evenly applied to minimize esophageal trauma. Repeated lubrication of these sites is recommended and important to maximize performance.

9. Never forcefully rotate the DSB. When significant force is encountered, never continue with the maneuver. Reduction and straightening with added lubrication decrease resistance during scope advancement.

Discovery SB proximal end showing ergonomic grips, lubrication port and Gentle-lock coupler features.

Spiral Enteroscopy: Prospective Multicenter U.S. Trial in Patients with Small Bowel Disorders

Morgan DR[1], Upchurch BR[2], Draganov PV[3], Binmoeller KF[4], Haluszka O[5], Jonnalagadda S,[6] Okolo PI[7], Grimm IS[1], Chiorean MV[9]

University of North Carolina, Chapel Hill, NC [1] – Cleveland Clinic, Cleveland, OH [2] – Shands Healthcare at the University of Florida, Gainesville, FL[3] – California Pacific Medical Center, San Francisco, CA[4]– Fox Chase Cancer Center, Philadelphia, PA[5] – Barnes Jewish Hospital/Washington University, St. Louis, MO[6] – Johns Hopkins Hospital, Baltimore, MD[7] – Indiana University Hospital, Indianapolis, IN[8]

Abstract

Introduction: Deep enteroscopy (DBE, SBE) has revolutionized management of patients with mid-small bowel disorders. Spiral enteroscopy (SE) is a novel approach coupling a standard balloon enteroscope with a spiral overtube. Aims of the present study were to determine the performance, yield and safety of SE in patients with suspected or established small bowel pathology.

Aims and Methods: Prospective, multicenter study with centralized standard database. Patients referred for anterograde enteroscopy were eligible. Patients with a history of esophageal stricture, advanced cirrhosis, or coagulopathy were excluded. The depth of insertion was measured using a standard algorithm. The mean adjusted diagnostic procedure time was calculated for all procedures: total time minus therapy time.

Results: 148 patients were enrolled at 10 centers in the U.S. with a median age of 68 (42% male). Co-morbid conditions were common: CAD 37.4%, CHF 12%, COPD 16%, and prior abdominal/pelvic surgery 55%. Chronic medication use: ASA 27%, clopidogrel 12%, warfarin 6.3%. Obscure GI bleeding (72%) was the most common indication, of which 32% were overt and 62% had been transfused within 6 months. Prior diagnostic evaluations: CE 84% (66% abnormal), EGD 84%, colonoscopy 91%, push enteroscopy 29%, DBE/SBE 12.5%. Spiral enteroscopy beyond the LOT was successful in 96% of procedures. The mean MAC doses: propofol 326mg (median 200mg), fentanyl 68mcg, midazolam 3.1mg. The median depth of insertion beyond the LOT was 250cm (range 80-600cm), with estimated SB segment depths: jejunum (proximal 6%, middle 12.3%, distal 28.8%) and ileum (proximal 44%, middle 6.2%). The terminal ileum was visualized in 1 subject.

The mean total procedure time was 45.0 minutes for all procedures, and 35.4 minutes for diagnostic procedures. The adjusted diagnostic procedure time for all procedures was 34.4 minutes. Fluoroscopy was limited (13%). The diagnostic yield was 65%, of which 48% had more than one abnormality. 62.3% of findings were localized beyond the proximal jejunum (35% mid-jejunum, 20% distal jejunum, 7.3% ileum). The most common findings: angioectasias (61.5%), inflammation (7.5%), neoplasia (6.8%). APC ablation accounted for 64% of interventions. The most common adverse events at 24 hours were: sore throat (28.3%), swallowing discomfort (24%), and abdominal bloating/discomfort (19%). There were no serious adverse events (perforation, pancreatitis, ileus, death).

Conclusion: Spiral enteroscopy appears to be safe and effective for evaluation of the small bowel. The procedure duration (35, 45 minutes) and depth of insertion (250cm) compare favorably with other deep enteroscopy techniques (DBE, SBE).

Submitted to DDW® 2009

Severe Complications of Spiral Enteroscopy in the First 1750 Patients

Akerman, Paul A.[1]; Cantero, Daniel[2]

University Gastroenterology, Providence, RI, USA[1] - National Hospital of Paraguay, Asuncion, Paraguay[2]

ABSTRACT

Introduction: Serious complications of deep small bowel enteroscopy occur infrequently. In published series, severe complications occur in deep small bowel enteroscopy in 0.3% to 4% of cases.

Aims and Methods: The aim of this study is to publish all recognized serious complications occurring during spiral enteroscopy. There were 1,750 patients who underwent spiral enteroscopy from May 2007 until November 2008. Cases have been performed in North America and Europe. Data was collected from device representatives and a survey of device users. The device used in all cases was the Discovery SB which is 118cm long with a hollow spiral 5.5mm high and 22cm long with a scope coupler on the proximal end. The Discovery SB has an outer diameter of 16mm and an internal diameter of 9.8 mm. The enteroscopes used in the examinations were 9.2mm Olympus SIF-180 and 9.4mm Fujinon EN450T-5 200cm enteroscopes. Severe complications were defined as pancreatitis, non-transient intussusception, severe pain after the procedure requiring admission to the hospital, bleeding requiring transfusion or admission to the hospital, cardio-pulmonary arrest during a procedure and perforation.

Results: There were no reported complications of pancreatitis, esophageal or gastric perforations, severe bleeding requiring transfusion, cardio-pulmonary arrests or deaths during or resulting from the spiral enteroscopy procedures. There were 7 severe complications (0.4%) reported as a result of the procedure. Six were small bowel perforations (0.34%). All were recognized immediately when the scope tip entered the peritoneum. Of these, three small bowel perforations occurred in the duodenum and three occurred in the jejunum. All perforations occurred while pushing to advance the scope through the stationary overtube. None of the perforations occurred during therapeutic interventions. None of the perforations occurred during rotation of the overtube to pleat the small bowel. Three of the perforations occurred when the experience of the physician was less than 10 cases. One patient experienced severe pain after the procedure and was admitted for observation. The patient did not require intervention and was later discharged.

Conclusion: The overall severe complication rate was 0.4% and a perforation rate of 0.34%. All of the perforations were recognized immediately when the scope tip visualized the peritoneum. Perforations may be minimized by advancing the enteroscope only when the lumen is clearly visualized.

Submitted to DDW® 2009

Safe and Rapid Intubation of the Distal Small Bowel Using the Discovery SB® Overtube Device during Small Bowel Enteroscopy: Results of the Spiral Enteroscopy Training Initiative

Jonathan M. Buscaglia, MD,[1, 2] Kerry B. Dunbar, MD,[1] Patrick I. Okolo, III, MD, MPH,[1] Joel Judah, MD,[4] Jesus Pangtay, MD,[3] Peter V. Draganov, MD[4]

Johns Hopkins University School of Medicine, Johns Hopkins Hospital, Department of Medicine, Baltimore, Maryland USA [1] - State University of New York, Stony Brook University Medical Center, Department of Medicine, Stony Brook, New York USA [2] - Clinica De Diagnosticos Pangtay, S.C. Tampico, Tamaulipas, Mexico [3] - University of Florida School of Medicine, Shands Hospital, Department of Medicine, Gainesville, Florida USA [4]

Abstract

Introduction: Indications for small bowel (SB) enteroscopy are increasing, but advancing the endoscope to the distal small intestine remains challenging. The Endo-Ease Discovery® SB device (*Spirus Medical*, Stoughton, MA), a novel spiral-shaped overtube FDA-approved for small bowel enteroscopy, may allow for simple and quick intubation of the ileum comparable to current methods.

Aims & Methods: To evaluate ease-of-use, safety, and efficacy of the Discovery SB during small bowel enteroscopy. 33 endoscopists without prior Discovery SB experience from 19 academic centers along with 2 Spirus instructors performed SB enteroscopy in human patients as clinically indicated during 1 of 4, 2-day training modules. All procedures performed without endo-tracheal intubation. Data was collected prospectively. Patient demographics, indication, depth and time to maximal insertion, total procedure time, and findings were recorded. Any trauma was documented during scope withdrawal and scored 0-5 (0=no trauma, 1 = edema/ erythema, 2=superficial hematoma/erosion, 3=superficial laceration, 4=deep laceration, 5=perforation). Overall means were calculated; Day 1 and Day 2 results were compared. Data was analyzed using 2-tailed t-test or rank-sum test for non-normally distributed data.

Results: 90 procedures were successfully performed in 95 patients (72.6% women; mean age = 48.8 ± 14.2 years). The most common indication was chronic abdominal pain. Mean BMI was 28.4 ± 17.2 with median Mallampati (M)--airway assessment--score=2 (range=1-4). Endoscopists performed a mean of 5 cases. Mean time required for device to engage SB was 10 ± 5.5 minutes, with mean time to maximal scope insertion of 20.9 ± 6.4min. Mean depth achieved was 262 ± 57.4cm beyond the ligament of Treitz. Total procedure time was 33.6 ± 8.0min. In 83.9%, 89.3% and 78.5% of patients, trauma score less than or equal to 2 was recorded in esophagus, stomach, and intestine respectively. There were no perforations. Trauma score greater than 2 was documented in 3 out of 5 of patients with a M- score of 4, versus 4 out of the 28 patients with a M-score of 1 (p=0.075). There were no statistically significant associations between trauma score and the following: age, BMI, time to SB engagement, depth of insertion, time to maximal insertion, total procedure time, or Day 1 vs. Day 2 procedures. Depth of insertion was significantly greater among endoscopists on Day 2 vs. Day 1 (276.9 ± 53.7 vs. 252 ± 58cm, respectively; p=0.043). In 88.9% of cases, endoscopists rated the quality of withdrawal, position, and control in the intestine greater than or equal to 4 (scale of 1-5; 5=excellent, 1=poorest).

Conclusion: The Discovery SB allows for safe and easy advancement of the enteroscope into the distal small bowel. Maximum depth of insertion utilizing spiral enteroscopy is comparable to balloon enteroscopy while taking less time. The device is easy to use and provides deep penetration of the small intestine in as few as 5 training cases.

Accepted at ACG® 2008

EDITORIAL

Spiral enteroscopy: a new twist on overtube-assisted endoscopy

The spiral is a spiritualized circle. In the spiral form, the circle, uncoiled, unwound, has ceased to be vicious; it has been set free.

Vladimir Nabokov

Until recently, the small bowel remained beyond the reach of direct endoscopic inspection outside the operating room. No matter how hard the endoscopist pushed a floppy tube, the twists and contours of the gut eventually ganged up, loops formed, and forward motion ended. Novel endoscope designs, like the Sondé enteroscope that relied on gut motility to move the tip through the bowel, proved too limiting to ever attain widespread use. The use of semirigid overtubes was fraught with complications, often pinching or creating shearing forces at the overtube tip.[1] Ultimately, the devices did not enable much deeper insertion than standard push enteroscopy.[2] Variable stiffness enteroscopes offered marginally deeper insertion without an overtube, but did not clearly improve diagnostic yield, and they never made it into widespread commercial production.[3] While other areas of GI endoscopy evolved and flourished, small-bowel imaging remained the province of the radiologist.

Deep small-bowel imaging emerged from the barium age with the advent of capsule endoscopy. Although it is a quantum leap beyond contrast studies, capsule endoscopy still does not offer the ability to insufflate the gut or repeatedly inspect suspicious areas, much less perform biopsies or apply therapy. Furthermore, the erratic nature of capsule passage may lead to incomplete visualization of portions of the small bowel. Enter double-balloon enteroscopy (DBE) (Fujinon, Wayne, NJ) in 2001 as the first endoscope system that could reliably pass deeply into the small bowel. The device allows significantly greater direct endoscopic visualization of the small bowel, with reported average depths of antegrade insertion more than 200 cm beyond the ligament of Treitz, and about 130 cm proximal to the ileoceal valve when inserted anally.[4]

Visualization of the entire small bowel has been rarely reported from the antegrade approach only, but more frequently by combining an antegrade and a retrograde procedure. Yamamoto et al[5] reported achieving total enteroscopy by combined routes in 86% of patients in whom it was attempted. May et al[6] reported 45% total enteroscopy success. Single-balloon endoscopy (SBE) (Olympus America, Center Valley Pa), an iteration of DBE that simply forgoes the second balloon at the tip of the endoscope, arrived soon after DBE and also allows deep enteroscopy. Depth of insertion of SBE has been less well studied than with DBE, but at least 1 case of total enteroscopy with SBE has been reported.[7]

Despite its success, balloon enteroscopy has been slow to catch on in the United States, even at major referral centers. The reasons for this are not immediately clear, especially when groups offering diagnostic capsule enteroscopy proliferate. DBE and SBE may lack traction because of the perceived long learning curve for the technique, or due to a reluctance to purchase the additional equipment that is necessary. However, it more likely relates to the long procedure times reported (well over an hour in most series), combined with relatively low reimbursement.

> Instead of "pushing a noodle," the spiral overtube pulls the small bowel over an essentially stationary endoscope. Its simplicity adds to its appeal.

Certainly there appears to be a need for a simpler, faster method for performing deep enteroscopy; and the idea of an "active" overtube is not new. Devices originally designed to speed colonoscopy have been modified for enteroscopy. The ShapeLock device (USGI, Palo Alto, Calif), a multi-linked, flexible overtube that can be converted into a rigid conduit by tensing connecting cables with a lever, was originally designed to reduce looping during difficult colonoscopies. It was modified and used successfully in small trials for enteroscopy.[8] However, its large outer diameter as well as production and marketing decisions relegated it to "wait and see" status. The Spirus Discovery threaded overtube (Spirus Medical Inc, Stoughton, Mass), which was also originally designed (and has been commercially available) as a colonoscopy aid, was recognized by a group of intrepid endoscopists as a tool that may have utility in the small bowel. The article by Akerman et al[9] in this month's *Gastrointestinal Endoscopy* represents the results of their initial investigation.

0016-5107/$36.00
doi:10.1016/j.gie.2008.09.011

In this proof of concept case series, the investigators used a 130-cm flexible plastic overtube with an outer diameter of 17.5 mm, and a 5-mm thread at the tip (total maximum diameter 18.5 mm), along with a 160-cm pediatric colonoscope to examine 27 patients with obscure GI bleeding. The overtube could not be passed in 2 patients because of concerns about a Schatski's ring in one and difficulty intubating the esophagus in another. They describe reaching an average depth of insertion of 176 cm beyond the ligament of Treitz (range 80-340 cm), with an average procedure time of 36.5 minutes (range 19-65 minutes). Bleeding sites were identified in 9 of 25 patients (36%) and treated in 8. There were no major complications, although sore throat and esophageal mucosal injuries were noted in 22% and 28%, respectively. No direct mention was made of the difficulty or ease of the procedure; however, the authors describe the device as enabling a slow, controlled withdrawal during which bipolar cautery was applied to bleeding sites.

The investigators intended first and foremost to show that spiral enteroscopy, as it is fittingly called, can reliably allow endoscopic visualization of a significant portion of the proximal small bowel. Furthermore, they hoped to show that this could be done safely and in a time-efficient manner.

Two of these endpoints appear to have been reached. The average procedure time in this series approximates times reported for standard push enteroscopy, with or without an overtube, and is about half the time we expect to spend doing DBE or SBE. Of course, the procedure duration is largely controlled by the operator. The study suggests that the maximum depth reachable with spiral enteroscopy is fairly obvious to the operator and further attempts at advancement gain no additional ground. This occurs either because enough small bowel has pleated onto the overtube that the threads slip with additional rotation or the overtube simply will not turn further. The point of maximal insertion with DBE is less clear. Even at depths of 200 cm or more, repeating cycles of advance and withdrawal may result in additional gain, especially when modifications such as insertion of a stiffening wire or application of abdominal pressure are added. Yamamoto describes completing total antegrade enteroscopy only after persisting more than 4 hours (personal communication). It remains unclear from the current literature what depths and yields would be achieved if DBE or SBE were limited to 30 minutes.

Spiral enteroscopy appears to be reasonably safe, at least in this small series. Although follow-up was not ideal, no major complications were reported. Sore throat and mucosal abrasions would be expected with manipulation—especially prolonged rotation—of a large overtube. No pinch or shearing injuries from the interface of the overtube and the endoscope were reported, possibly because the tip of the overtube had been fitted with a soft, snug seal. It is notable that small-bowel trauma from the rotating threads was not reported and that the device did not appear to cause torque injury to the stomach or intestine. Again, no formal imaging or other investigation beyond soliciting patient complaints was pursued. The investigators chose not to proceed in a patient with a Schatski's ring and another in whom initial intubation proved difficult. With the device in general use, such restraint may not be universal.

Newer versions of the overtube have a smaller outer diameter and a softer thread that comes in a standard version and a lower-profile version, so esophageal trauma may be less of a problem. The trade-off, however, is that the smaller overtubes can only be used with dedicated enteroscopes with an outer diameter no greater than 9.4 mm (such as the enteroscopes designed for single- and double-balloon procedures, which retail for $37,000 and $47,000, respectively) and will not be usable with the ''off the shelf'' pediatric colonoscope. In the initial series, one physician rotated the overtube and another guided the endoscope. The 2-physician model is not practical in most endoscopy suites, and it remains to be seen how easily one station—either overtube rotation or endoscope control—can be handled by a nurse or technician. Finally, all patients underwent propofol sedation for the procedure, and it is unclear whether many patients would tolerate spiral enteroscopy with midazolam and fentanyl sedation.

The less certain endpoint—and this is true with almost all reports of deep enteroscopy techniques—remains the actual depth of insertion. The authors describe reaching depths of up to 300 cm beyond the ligament of Treitz, with an average depth reached of 175 cm. These distances are similar to those reported, at least in the North American experience, to double-balloon enteroscopy. However, reports of depth of insertion in deep enteroscopy are like reports from fishermen concerning the size of the fish that got away: they are almost entirely subjective, have not been studied in any standardized manner, and are probably exaggerated. Measuring depth of insertion in DBE relies on adding the sum of multiple advancements minus estimates of slippage.[10] Although 1 cycle may be fairly accurate, the accumulated errors, especially toward the end of the procedure, when slippage may exceed advancement, make these estimates highly suspect. At a recent international consensus meeting on DBE, the participants just barely achieved a 50% vote in favor of using the cumulative cycle technique for estimating depth of insertion, and then only because no better technique appears to exist.[11] Radiographic estimates and measuring during withdrawal are equally unreliable. In practice, many centers in which DBE is performed have abandoned attempts at formal measurement and rely on estimates of the general segment of bowel reached (ie, midjejunum, proximal ileum, etc). In a recent article on SBE, no mention at all was made of

depth of insertion.[7] During spiral enteroscopy, measurement of depth of insertion relies on visual estimates of the amount of small bowel that is seen passing the tip of the scope during both insertion and withdrawal. Comparing depth of insertion in vivo to the experience with a pig intestine model may help in making these estimations, but it does not guarantee accuracy.[12] That said, in one abstract in which 2 patients with tumors were identified by spiral enteroscopy, the estimated depth of the lesion closely matched the location at surgery.[13]

Although it was not a stated endpoint, the diagnostic yield of spiral endoscopy in this series (33%) appears low, at least when compared to data from DBE series, which report identifying bleeding sources in about 75% of cases.[14] These yields seem low, even compared to older literature on push enteroscopy, which reports identifying obscure bleeding in 45% to 80% of cases.[15] This may mean that actual depth of insertion was less than estimated, or, as the authors point out, this may be a factor of the patient population and patient selection. This Central and South American group of patients had not undergone the same rigorous work-up prior to deep enteroscopy as those patients in North American, Japanese, and European series (ie, no mention of transfusion requirement prior to the study, no capsule enteroscopy, CT scanning, etc). Clearly, formal studies in other populations are needed.

Nevertheless, spiral enteroscopy represents a dramatic shift not only in how we perform small-bowel endoscopy but in how we think of endoscopy in general. Instead of ''pushing a noodle,'' the spiral overtube pulls the small bowel over an essentially stationary endoscope. Its simplicity adds to its appeal. Combine this with relatively rapid achievement of maximum depth of insertion, which makes deep enteroscopy more financially appealing to busy endoscopy centers, and spiral enteroscopy begins to sound like it may earn a place on the endoscopists' growing shelf.

However, as with all new technologies, impediments and unintended consequences can cast shadows on even the most promising devices. Can we be sure that the rotational forces of the overtube won't traumatize the bowel or other structures in other circumstances, such as inflammatory bowel disease, extensive abdominal surgery, etc? Can the device be removed quickly in case of an emergency? What is the learning curve for the average endoscopist? What conditions will render spiral enteroscopy unsuccessful or even dangerous?

Ultimately, we will have to wait for additional studies in other patient populations, performed by investigators without a financial interest in the technology in order to better assess the diagnostic yield of spiral endoscopy. This technology, along with any other new enteroscopy devices, will need to be measured against balloon enteroscopy, which represents today's reference standard for nonsurgical enteroscopy, both in terms of an objective measure of depth of insertion as well as diagnostic and therapeutic outcomes.

Those of us who perform deep enteroscopy look forward to seeing additional studies of spiral enteroscopy. We will then be able to tell whether it represents a real advance or is another idea that held promise but fails to deliver. Ultimately, we await a device—whether it is a modification of the spiral system or something completely different—that will allow reliable, total nonsurgical enteroscopy in one session. Until that time, we will continue to use unsatisfying surrogate markers like depth of insertion and diagnostic yield to tell us how far we are along that path.

DISCLOSURE

The authors disclosed financial relationships relevant to this publication: D. B. Schembre, A. S. Ross: Speaker honoraria and travel reimbursement from Fujinon and Spirus. D. B. Schembre: Speaker honoraria from Olympus.

Drew B. Schembre, MD, FASGE
Andrew S. Ross, MD
Virginia Mason Medical Center
Seattle, Washington, USA

Abbreviations: *DBE, double-balloon enteroscopy; SBE, single-balloon enteroscopy.*

REFERENCES

1. DiSario JA, Petersen B, Tierney W, et al. Enteroscopes. Gastrointest Endosc 2007;66:872-80.
2. Taylor AC, Chen RY, Desmond PC. Use of an overtube for enteroscopy: does it increase depth of insertion? A prospective study of enteroscopy with and without an overtube. Endoscopy 2001;33:227-30.
3. Harewood GC, Gostout CJ, Farrell MA, et al. Prospective controlled assessment of variable stiffness enteroscopy. Gastrointest Endosc 2003;58:267-71.
4. Gross S, Stark ME. Initial experience with double-balloon enteroscopy at a U.S. center. Gastrointest Endosc 2008;67:890-7.
5. Yamamoto H, Kita H, Sunada K, et al. Clinical outcomes of double-balloon endoscopy for the diagnosis and treatment of small-intestinal diseases. Clin Gastroenterol Hepatol 2004;2:1010-6.
6. May A, Nachbar L, Ell C. Double-balloon enteroscopy (push-and-pull enteroscopy) of the small bowel: feasibility and diagnostic and therapeutic yield in patients with suspected small bowel disease. Gastrointest Endosc 2005;62:62-70.
7. Kawamura T, Yasuda K, Tanaka K, et al. Clinical evaluation of a newly developed single-balloon enteroscope. Gastrointest Endosc 2008 Jul 1 [Epub ahead of print].
8. Kozarek R, Schembre D, Spaulding W, et al. Initial application of the ShapeLock™ endoscopic guide for small bowel enteroscopy [abstract]. Gastrointest Endosc 2005;61:AB172.

9. Akerman PA, Agrawal D, Chen W, et al. Spiral enteroscopy: a novel method of enteroscopy by using the Endo-Ease Discovery SB overtube and a pediatric colonoscope. Gastrointest Endosc 2009;69:327-32.
10. May A, Nachbar L, Schneider M, et al. Push and pull enteroscopy using the double-balloon technique: method of assessing depth of insertion and training of the enteroscopy technique using the Erlangen Endo-Trainer. Endoscopy 2005;37:66-70.
11. Sugano K, Marcon N. The first international workshop on double balloon endoscopy: a consensus meeting report. Gastrointest Endosc 2007;66(Suppl):S7-11.
12. Akerman PA, Cantero D, Bookwalter WH, et al. A new in vitro porcine model for spiral enteroscopy training: the Akerman enteroscopy trainer [abstract]. Gastrointest Endosc 2008;67:AB264.
13. Akerman PA, Cantero D, Avila J, et al. The spiral enteroscopy experience in 101 consecutive patients: safety and efficacy using the Discovery SB [abstract]. Gastrointest Endosc 2008;67:AB92.
14. Kamal A. Double-balloon enteroscopy: ready for prime time? Gastrointest Endosc 2008;67:898-901.
15. Wilmer A, Rutgeerts P. Push enteroscopy: technique, depth and yield of insertion. Gastrointest Endosc Clin North Am 1996;6: 759-76.

Small Intestinal Enteroscopy: Coding and Reimbursement Considerations

The Endo-Ease Discovery® SB is part of the **Endo-Ease® Endoluminal Advancement System**, a revolutionary, patented "rotate-to-advance" technology in flexible endoscopy from Spirus Medical. For the enteroscopist, the Endo-Ease Discovery SB overcomes the technical limitations associated with examination of the long, convoluted configurations of the small bowel. To help answer customers' coding and reimbursement questions about Spiral Enteroscopy™, the following information is provided for educational and strategic planning purposes. Please speak with your Spirus Medical sales professional for personal service or additional information.

Product Description

The Endo-Ease Discovery SB is a single-use, disposable 48 French, 118 centimeter overtube with a nominal 5.5mm (standard profile) or nominal 4.5mm (low profile) raised helical element at its distal end. Use of this technology with an existing compatible enteroscope allows all standard therapies to be employed.

The Discovery SB offers the option to stabilize the small bowel at any point the physician chooses while the scope is independently advanced. Spirus Medical's proprietary Vari-Flex Shaft is more uniformly flexible at the distal end and transitions gradually to a less flexible proximal end, resulting in an optimal integration of torque transmission and flexibility.

Regulatory Clearance

The Spirus Medical Endo-Ease Endoscopic Overtube is indicated to aid endoscopic insertion and advancement to the mid-ileum during diagnostic and therapeutic upper GI endoscopy and enteroscopy. The Endo-Ease is used with an endoscope of appropriate diameter and length (such as an enteroscope or pediatric colonoscope*) *(K080050, April 6, 2008)*[1].

Clinical Significance

To date, endoscopic examination of the small intestine, extending into the jejunum and/or ileum, has been hampered by serious technical and procedural limitations. In clinical evaluations, the Spirus Medical Endo-Ease overtube has been proven to be effective in achieving an insertion depth of 400cm beyond the Ligament of Treitz, when used with a slim enteroscope. The Endo-Ease Discovery SB offers enteroscopists a technology solution that not only allows diagnostic visualization of the small bowel to the mid-ileum, but also permits tissue acquisition and therapeutic intervention. The appropriately selected patient is an individual referred to a Gastroenterologist for diagnosis and/or therapeutic intervention of a persistent intestinal complaint without an etiology uncovered by standard EGD and/or colonoscopy[2].

Health Policy Considerations

Coding the professional and technical components of a small intestine endoscopy relies upon details in the patient's medical record, including the patient's chief complaint for the principal ICD-9-CM diagnosis code(s), past medical history for concomitant ICD-9-CM diagnoses code(s), and the enteroscopist's procedure note for appropriate HCPCS considerations. While Spirus Medical believes the following information to be correct, it is shared for educational and strategic planning purposes only. The actual selection of codes remains the sole responsibility of the provider. Since individual insurers have different requirements and since coding information is subject to change without notice, providers are encouraged to speak with their payers as needed.

Physician Coding Considerations

The 44360 family of Level I CPT codes describes small-intestinal endoscopy beyond the second portion of the duodenum, not including the ileum; whereas the 44376 family of Level I CPT codes describes small intestine endoscopy beyond the second portion of the duodenum, including the ileum.[3] To appreciate the range of CPT coding considerations for enteroscopy, physicians and their professional coders are encouraged to review a current copy of *CPT 2008* issued by the American Medical Association. Common enteroscopy CPT codes include, but are not limited those listed in the table at right.

CPT	Definition	Facility RVU Total
44360	Small intestinal endoscopy, enteroscopy beyond second portion of duodenum, not including ileum; diagnostic with or without collection of specimen(s) by brushing or washing (separate procedure).	4.28
44361	With biopsy, single or multiple	4.71
44363	With removal of foreign body	5.61
44365	With removal of tumor(s), polyp(s) or other lesion(s) by hot biopsy forceps or bipolar cautery.	5.29
44376	Small intestinal endoscopy, enteroscopy beyond second portion of duodenum, including ileum; diagnostic, with or without collection of specimen(s) by brushing or washing (separate procedure).	8.14
44377	With biopsy, single or multiple	8.68
44378	With control of bleeding (eg, injection, bipolar cautery, unipolar cautery, laser, heater probe, stapler, plasma coagulator)	12.01
44379	With transendoscopic stent placement (includes predilation)	11.22
44799	Unlisted procedure, intestine	Carrier Priced

Source: CPT 2008. Current Procedural Terminology (CPT®) is a registered trademark of the AMA.

Hospital Coding & Reimbursement Considerations

Since enteroscopy is typically an outpatient procedure, facility coders would consider the following CPT codes, Ambulatory Payment Classifications (APCs) and associated 2008 Medicare National Average Payments.

APC	Ambulatory Payment Classification (APC) Description	Relative Weight	2008 CMS Nat'l Average
142	Small Intestine Endoscopy (includes CPTs 44360, 44361, 44363, 44365, 44376, 44377, 44378).	9.529	$607
153	Peritoneal & Abdominal Procedures (CPT 44799)	25.6947	$1,636
384	GI Procedure with Stents (CPT 44379)	24.9814	$1,591

Source: Hospital Outpatient Prospective Payment System, final rule. Federal Register, November 27, 2007, pages 67045-6.

Dependent upon individual payer contract terms, the following Level II HCPCS codes as indicated in the table may be considered.

HCPCS	Description
A4270	Disposable endoscope sheath, each.
C1726	Catheter, balloon dilatation, nonvascular.

Source: American Medical Association. HCPCS 2008, Medicare's National Level II Codes.

* *Only available for enteroscopes 200cm x 9.1mm–9.5mm outer diameter.*

[1] *www.fda.gov*

[2] *Eisen GM et al. Enteroscopy. Gastrointestinal Endoscopy 2001; 53:871-3.*

[3] *ASGE Practice Management Committee. Coding for "deep enteroscopy" procedures in an era of emerging technology. Gastrointestinal endoscopy, 2008, 67, 3, 391-393.*

1063 Turnpike Street
Post Office Box 258
Stoughton, MA 02072

888-297-7220
SpirusMed.com

At Spirus Medical, we are committed to advancing the diagnosis and treatment of gastrointestinal (GI) disorders with our "Rotate-to-Advance" endoluminal technology platform. To appreciate the ease and rapidity of the Endo-Ease Discovery SB, please schedule a product demonstration with your local Spirus Medical sales professional.

spirus™ medical

Introduction

Learning the Endo-Ease Vista® technique is rather simple. However, like anything new you'll need to temporarily slow down a bit before resuming your normal rhythm. Keep in mind that the spiral element serves mainly for positioning and stabilization.

This guide compiles physician preferences found to be useful in the handling of the Endo-Ease Vista. This compilation visually summarizes some Vista techniques for colononoscopy / ileoscopy and also hi-lights useful points for installing the device on your scope, inserting it into the patient and intra-procedural considerations.

When first learning this technique you will notice a slight difference in tactile feedback. Start with easier screening patients to get a feel for the system before performing more difficult cases. Any contraindications for colonoscopy would preclude the use of this device.

This guide should not be used in lieu of reading the instructions for use included with each device.

Installation

The Endo-Ease Vista will fit endoscopes with an outer diameter measuring 10.5mm - 11.6mm. If you are using a scope with variable stiffness, set it to the softest setting.

The proximal end of the Vista should be lined up to the 115cm - 120cm mark on the scope. This is the minimum setting but the scope can be set a little further into the Vista to expose more of the distal insertion tube.

Squeeze a generous amount of lubricant into the coupler located on the proximal end of the device. Hold the Endo-Ease tip over a 4x4 or drape in order to collect the lubricant pushed through the device.

Work the lube back and fourth during installation before locking in place. Evenly spread lube over the spiral.

Ideally, insertion to the cecum should be performed while the Vista is coupled (locked) with the endoscope; however, some physicians prefer to back-load the Vista before insertion begins. The scope can then be independently inserted through the recto-sigmoid utilizing techniques preferred by the physician. The Vista is then rotated and pushed over the scope. Lock the Vista onto the scope at its115cm - 120cm mark and advance as a coupled unit.

Insertion

To insert, find the lumen with the angulation knobs, then rotate clockwise while gently pushing. Use of the water jet during insertion can help reduce friction and resistance. Minimal insufflation during insertion maximizes the performance of the device and patient comfort.

Like routine colonoscopy, abdominal counter pressure or patient positioning alterations may prove beneficial at certain times during insertion.

Procedure

Kinks and sharp bends in the Vista can cause resistance. Try to keep the coupled unit as straight as possible outside patient.

Slow down going through the sigmoid and left colon. This will allow for less looping, better set up of the device and less time getting through the remainder of the colon.

As with routine colonoscopy, be aware of very fixed or extremely angled recto-sigmoids, especially early on in the learning curve when you are developing new tactile skills.

Always maintain visualization by keeping the endoscope centered in the lumen, when advancing the Vista or the endoscope.

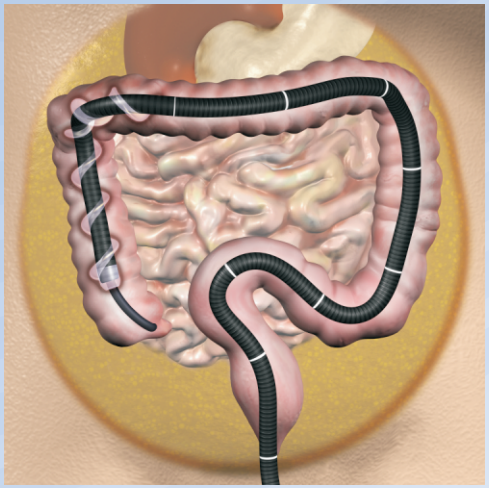

P/N 600-0011 REV. C

Endo-Ease vista™ retrograde

Techniques for Colonoscopy & Ileoscopy

spirus™ medical

spirus medical

Vista® Technique for Colonoscopy & Ileoscopy

The Vista can be back-loaded onto the scope before insertion begins. The scope can then be independently inserted through the recto-sigmoid utilizing techniques preferred by the physician. The Vista is then rotated and pushed over the scope. Lock the Vista onto the scope at its120cm mark and advance as a coupled unit.

Gentle clockwise turning and pushing to advance as soon as first spiral is engaged. Control device with your fingertips. Do not rely on a firm grasp to rotate.

Always keep scope centered in the lumen while minimizing insuflation.

Resistance to turn or excessive pain encountered.

Potential Loop, Tight Angle or Stricture
Do not push or try to rotate with excessive force to advance.

Rotate the Vista with gentle push to advance until it reaches the desired colonoscopic insertion point or until the device is inserted to the handle.

Sigmoid and Proximal to Cecum

Recto-Sigmoid

Disengage the Vista from the scope.
Advance the endoscope through the Vista.

Gently pull back coupled unit (counter-clockwise may be utilized as well). Re-advance with clockwise rotation and gentle push. Use standard techniques to advance.

Advance endoscope to the desired insertion point. Utilize hook-suction-pullback and other standard endoscopic techniques such as back and forth motions of the scope to tether the ileum.

Continued Resistance is Encountered
As in routine colonoscopy, conditions such as fixed recto-sigmoids, tight angles, strictures and tethering by adhesions may make insertion extremely difficult. It may be wise to re-evaluate the patient as a candidate for colonoscopy.

ILEAL INTUBATION

If an external length of Vista prevents full scope insertion, disengage unit and rotate clock-wise while pushing forward over the scope (guide-wire maneuver).

Lesion proximal to sigmoid.

Perform multiple passes leaving Endo Ease in place.

Withdrawal: Retract endoscope to original fixation point. Lock in place. Use counter-clockwise rotation to withdraw coupled unit.

KEY

- Fundamental Path
- Challenges
- Options
- Caution